

Objective interpretation of dental disease in rabbits, guinea pigs and chinchillas

Use of anatomical reference lines

E. Boehmer; D. Crossley

Clinic of Veterinary Surgery and Obstetrics (Head of Department: Prof. Dr. U. Matis), Ludwig-Maximilians-University Munich, Germany; Division of Surgery (Principal: P. Boydell), Animal Medical Centre, Chorlton, Manchester, UK

Key words

Malocclusion, normocclusion, radiography, assessment, long-term prognosis, staging

Summary

Objective: Objective interpretation of dental disease in rabbits, guinea pigs and chinchillas with the use of anatomical reference lines. **Material and methods:** Skull radiographs (laterolateral and dorsoventral view) of 528 small mammals (204 rabbits, 151 guinea pigs and 173 chinchillas) were measured and analysed exactly in connection with a thorough intra- and extraoral clinical examination. 464 animals showed variable signs of malocclusion whereas 64 animals had a normocclusion. The clinical and radiographic changes of 224 individuals (52 rabbits, 41 guinea pigs and 131 chinchillas) were additionally compared with post mortem findings. **Results:** Particularly the comparison of the prepared skulls with the radiographs of the identical animals enabled the acquirement of species specific anatomical reference lines, that facilitate the objective assessment of severity of dental disease in elodont species. **Conclusion and clinical relevance:** Using these reference lines the extent of malocclusion in rabbits, guinea pigs and chinchillas can be acquired more exactly and the results are reproducible by different examiners (staging). In addition to this these special lines facilitate to accurately monitor the progress of dental changes and thus to predict a probable long-term prognosis. The reference lines are absolutely applicable for daily use in practice.

Schlüsselwörter

Malokklusion, Normokklusion, Röntgen, Beurteilung, Langzeitprognose, Einteilung

Zusammenfassung

Gegenstand und Ziel: Objektive Interpretation von Zahnerkrankungen bei Kaninchen, Meerschweinchen und Chinchillas mithilfe anatomischer Referenzlinien. **Material und Methode:** Bei 528 kleinen Heimtieren (204 Kaninchen, 151 Meerschweinchen und 173 Chinchillas) wurden Röntgenaufnahmen des Kopfes in zwei Ebenen angefertigt und im Zusammenhang mit einer sorgfältigen intra- und extraoralen klinischen Untersuchung exakt analysiert und vermessen. 464 dieser Tiere zeigten unterschiedlich deutliche Anzeichen einer Malokklusion, während 64 Tiere ein gesundes Gebiss aufwiesen. Bei 224 Individuen (52 Kaninchen, 41 Meerschweinchen und 131 Chinchillas) wurden die erhobenen klinischen sowie röntgenologischen Veränderungen post mortem mit den jeweiligen Befunden an den präparierten Schädeln verglichen. **Ergebnisse:** Insbesondere durch die unmittelbare Gegenüberstellung des präparierten Schädels mit den zuvor angefertigten Röntgenaufnahmen des jeweils selben Tieres konnten spezielle tierartspezifische Referenzlinien erarbeitet werden, die es erlauben, Zahnerkrankungen bei Tierarten mit elodonten Backenzähnen nicht nur subjektiv, sondern auch objektiv zu erfassen. **Schlussfolgerung und klinische Relevanz:** Mithilfe dieser Referenzlinien kann das Ausmaß der Zahnerkrankungen bei Kaninchen, Meerschweinchen und Chinchillas exakt und auch von verschiedenen Untersuchern reproduzierbar erfasst werden (Staging). Darüber hinaus ermöglichen es die Linien im Rahmen einer Langzeitstudie, den weiteren Verlauf der Malokklusion relativ genau zu dokumentieren und somit eine eindeutigere Aussage hinsichtlich der Langzeitprognose zu stellen. Die Referenzlinien eignen sich somit gut für den Einsatz in der täglichen Praxis.

Correspondence to

Dr. Estella Böhmer
Chirurgische und Gynäkologische Kleintierklinik
der Ludwig-Maximilians-Universität München
Veterinärstraße 13
80539 München
Germany
E-Mail: e.boehmer@lmu.de

Objektive Interpretation von Zahnerkrankungen bei Kaninchen, Meerschweinchen und Chinchillas: Anwendung anatomischer Referenzlinien
Tierärztl Prax 2009; 37 (K): 250–260

Received: August 8, 2008
Accepted: January 25, 2009

Introduction

Dental diseases in rabbits and rodents are very common and often pose a challenge for the attending veterinarian. In this context, there have been numerous publications within the last two decades describing specific pathological changes seen in the different species (1–45). Many of these point out the importance of a thorough radiographic examination of the skull using multiple views and give some helpful advice on the treatment, but they rarely describe objective methods to ascertain the degree of pathological changes such as tooth elongation. Thus it has not been possible to accurately monitor the progress of these changes. This paper, however, illustrates a range of radiographic anatomical landmarks for the examination of rabbits, guinea pigs and chinchillas. With the help of these landmarks specific reference lines can be defined

which enable the veterinarian to discern the specific pathological changes and perform accurate measurements for long-term monitoring if necessary. Use of these anatomical reference lines greatly simplifies explanation of oral problems to the animal's owners, as they can clearly see the extent of changes. This permits them to better understand the treatment recommendations and any associated complications.

A specific reference line which demonstrates extraoral maxillary cheek tooth elongation (apical intrusion) in chinchillas was published by Crossley in 1995 and 1996 (8, 10). Five years later, Boehmer mentioned a similar basic reference line for rabbits and guinea pigs (1). These three lines turned out to be so helpful in objectively illustrating extra-oral maxillary cheek tooth problems on laterolateral radiographs that studies were extended to include dorsoventral views. On the basis of numerous measurements per-

Table 1

Radiographic (laterolateral and dorsoventral view each) and post-mortem examinations

| Radiographic Examinations | | | | |
|---------------------------|--------|------------|------------|---------------|
| | Rabbit | Guinea pig | Chinchilla | Total animals |
| With dental disease | 183 | 132 | 149 | 464 |
| Clinically healthy | 21 | 19 | 24 | 64 |
| Totals | 204 | 151 | 173 | 528 |
| Post mortem Examinations | | | | |
| | Rabbit | Guinea pig | Chinchilla | Total animals |
| Skull dissection | 52 | 41 | 131 | 224 |

Table 2 Reference lines (overview)

| | | Rabbit | Guinea pig | Chinchilla |
|--------------------------------|--|--|---|---|
| Lateral projection | Dorsal limitation of maxillary tooth apices (white line) | Proximal end of the nasal bone to occipital protuberance | Rostral end of the nasal bone to dorsal notch of the tympanic bulla (about three quarters of its height) | Dorsal margin of the maxillary incisor to middle of the tympanic bulla |
| | Occlusal plane (yellow line) | Rostral end of the hard palate to one third of the height of the tympanic bulla | Rostral surface of the mandibular incisor (normal length) to the notch of the tympanic bulla (about three quarters of its height) | Tip of the upper incisors to the tympanic bulla (about three quarters of its height) |
| | Ventral limitation of mandibular tooth apices (blue line) | No penetration of the ventral mandibular cortex | No penetration of the ventral mandibular cortex | No penetration of the ventral mandibular cortex |
| | Mismatch of the cheek tooth arcade (reliable sign of significant malocclusion) (red lines) | No regularity | Rostral displacement of the mandible | Caudal displacement of the mandible |
| Dorsoventral projection | Lateral limitation of the maxillary tooth arcade | Lateral margin of the maxillary first incisor's tip to medial edge of the mandibular ramus | Medial border of the maxillary incisor to the most caudolateral part of the ipsilateral mandible | Medial tip of the maxillary incisor to caudal extremity of the ipsilateral mandibular ramus |
| | Medial limitation of the maxillary tooth arcade | Lateral rim of the contralateral maxillary incisor to the lateral border of the tympanic bulla | – | – |

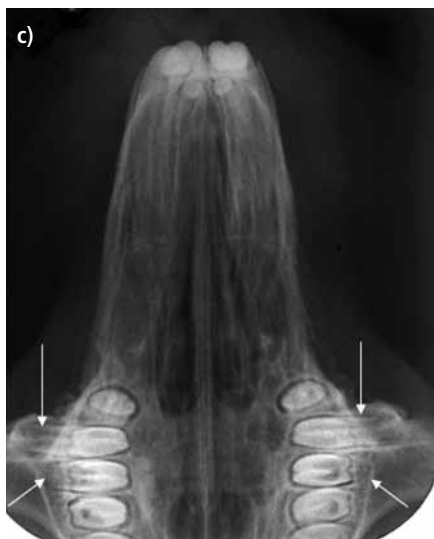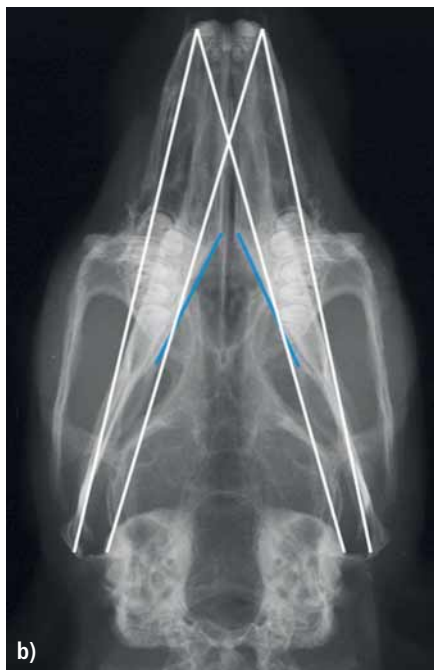
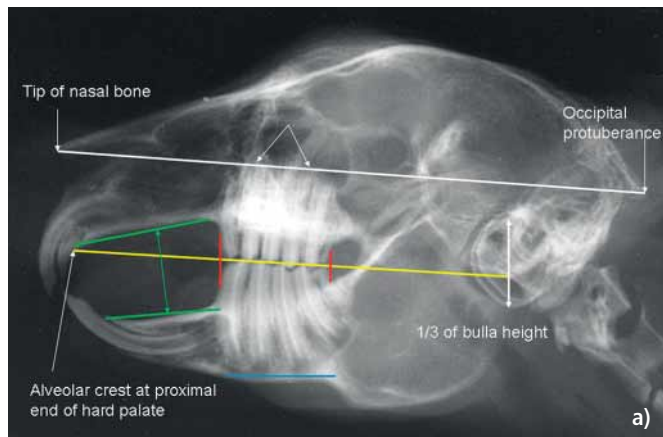


Fig. 1
Radiographic anatomical reference lines of a clinically healthy rabbit. See main text for explanation.
a) Laterolateral view;
b) dorsoventral view;
c) intraoral radiograph of the maxilla.

formed on radiographs of 528 lagomorphs and rodents with and without pathological dental changes (► Table 1), additional reference lines were acquired (► Table 2).

The reference lines presented in this paper represent those that have survived validation by clinical and radiographic follow-up plus post-mortem examinations performed on previously radiographed patients (► Table 1).

Radiographic screening

Whilst the presence of some dental problems can be determined by physical examination, the bulk of the teeth is embedded in the jaw. In order to detect whether or not a rabbit, guinea pig or chinchilla suffers from tooth elongation or other changes in dental morphology, it is best to initially obtain two radiographic views of the skull (laterolateral and dorsoventral). These screening views can normally be achieved using light sedation. It helps to obtain the laterolateral view with the mouth open a couple of millimetres as separation of the cheek teeth improves definition of the occlusal line. Additional views are usually indicated after screening but positioning for these is more complicated, so they are best obtained once the animal is fully anaesthetised (1, 2). When obtaining radiographs after placement of an endotracheal tube in rabbits, its location has to be taken into consideration as superimposition over the area of interest can obscure anatomy and pathological changes. Therefore the use of injectable anesthetic agents should be preferred. The technical requirements for an adequate radiographic examination of the skull and hints for an optimal positioning in different species had been described in detail in a previous two-section paper (1, 2).

Rabbit

Normal radiographic anatomy of the skull

In clinically healthy animals no dental structure should extend dorsal to a reference line that connects the proximal end of the nasal bone with the tip of the occipital protuberance on the lateral view (► Fig. 1a). In rabbits without pathological changes of the skull or teeth, another reference line runs parallel to the one previously mentioned, beginning at the rostral end of the hard palate (yellow line) mostly immediately caudal to the second incisor and extending caudally to pass through the tympanic bulla at approximately one third of its height. This line matches the occlusal plane in healthy rabbits. Although in this species six maxillary cheek teeth occlude with five mandibular ones, the maxillary and mandibular dental arcs are approximately the same length (red lines in ► Fig. 1a). Additionally, the apices of the mandibular cheek teeth should not penetrate the ventral mandibular cortex which should have a near even thickness beneath the first three cheek tooth apices (blue line). Remodelling of the ventral cortex adjacent to the tooth apices indicates that there is retrograde elongation of the

lower cheek teeth. Furthermore the palatine and mandibular bone plates should slightly converge rostrally in normal rabbits (green lines in ► Fig. 1a) the amount of convergence varying somewhat with breed skull type.

There are also some relevant reference lines on the dorsoventral view of the skull which add to the information obtained from lateral views. The first line connects the lateral margin of the maxillary first incisor's tip with the medial edge of the mandibular ramus on the same side caudally. Another line, which diverges slightly from the previous one, runs from the lateral border of the tympanic bulla to the lateral rim of the contralateral maxillary incisor (► Fig. 1b). With the exception of the tips of the apices of the significantly curved maxillary second and third cheek teeth (see arrows in ► Figure 1c), no part of any tooth should be located outside these two lines. The two blue lines in ► Figure 1b indicate the medial cortex of the mandible. This should be almost straight, smooth and even. The maxillary premolar anatomy is shown in ► Figure 1c without superimposition of the mandible and its associated teeth.

Dental disease

The applicability of these anatomical reference lines is demonstrated in ► Figures 2 and 3 which show radiographs of two rabbits with advanced dental disease. In ► Figure 2a, a distinct retrograde apical elongation of multiple maxillary cheek teeth can be seen, as indicated by the white arrows. Additional findings are a malocclusion of the incisor teeth with penetration of the palatal bone cortex by the apex of at least one of the maxillary first incisors (green arrow). There is also considerable bone loss in the mandibular incisor region suggestive of an intra-bony abscess (blue arrows).

Even if laterolateral radiographs are imperfectly positioned the reference lines can be approximated and remain valid as shown in ► Figure 2a. Although the second reference line in yellow cannot be drawn as precisely, it still shows that the occlusal plane is close to normal rostrally, but there is slight elongation of the clinical crowns of the maxillary molars.

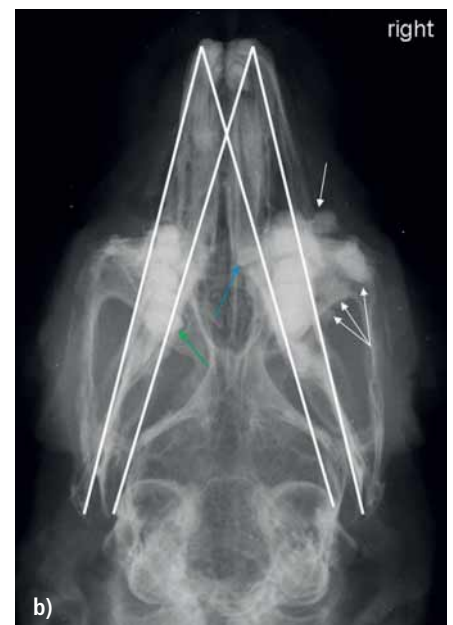
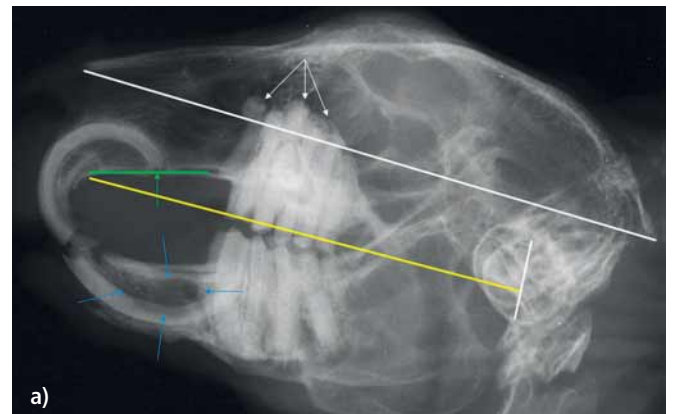


Fig. 2 Rabbit, 8 years, advanced stage of dental disease. See main text for explanation. a) Laterolateral view; b) dorsoventral view.

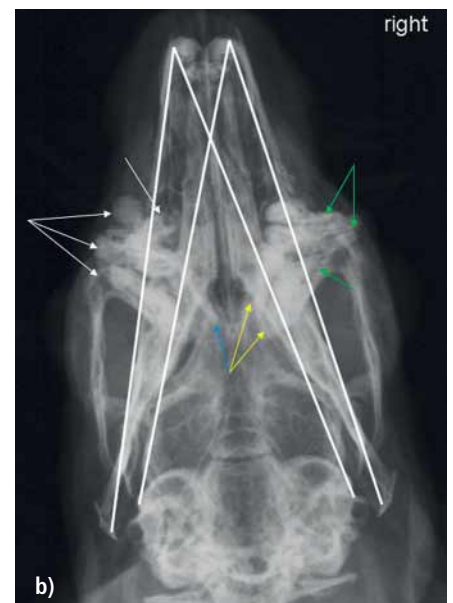
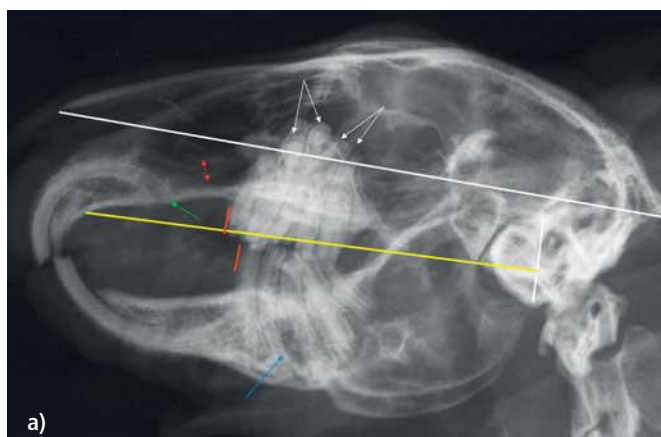


Fig. 3 Rabbit, 3 years, advanced stage of dental disease. See main text for explanation. a) Laterolateral view; b) dorsoventral view.

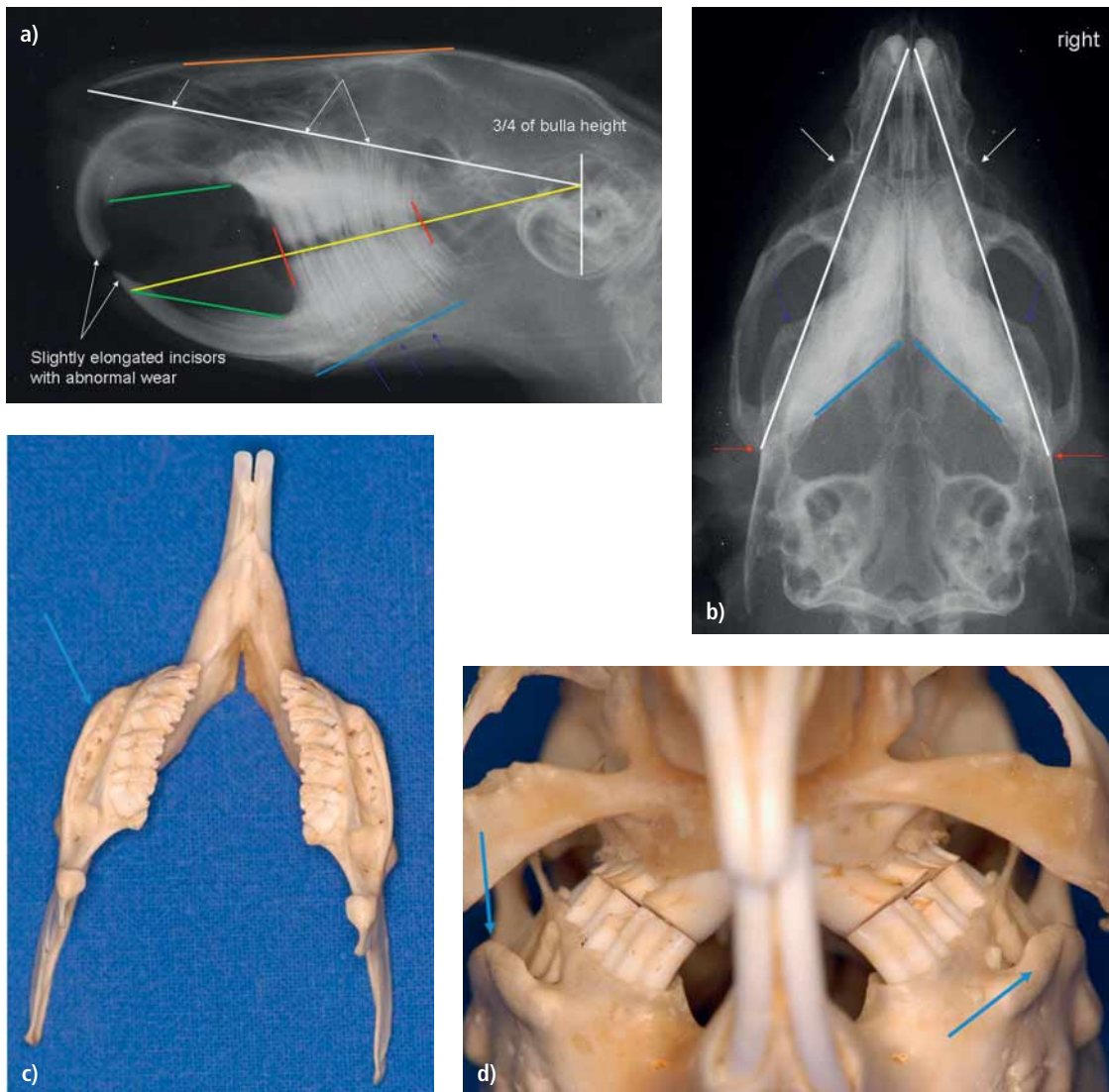


Fig. 4 Reference lines of a clinically healthy guinea pig. See main text for explanation. a) Laterolateral view; b) dorsoventral view; c-d) prepared skull.

The dorsoventral view of this rabbit (▶ Fig. 2b) objectively demonstrates pathological changes of the maxillary cheek teeth. The retrograde root elongation is distinctly seen to be primarily affecting the right side. Both the lacrimal and maxillary zygomatic processes have been deeply penetrated and overlain by the intruded root apices of elongated teeth. All but the last maxillary cheek tooth of this side show laterally displaced apices which are more radiodense than normal and have lost the normal apical structure. On the left side, the maxillary second molar is displaced medially (▶ Fig. 2b, green arrow). On the right side the medially displaced apex of the mandibular first cheek tooth (premolar 1), is also seen (▶ Fig. 2b, blue arrow).

Examination of the laterolateral and dorsoventral views in this case indicate that, as in many cases, additional radiographs are required for more accurate localization of the pathological changes. At least two oblique views (right and left side mirror image views) plus an intraoral image of the mandible are required

in this case to ascertain whether the mandibular first cheek tooth is involved in the lesion affecting the mandibular incisor.

The reference lines drawn in ▶ Figure 3a highlight the distinctly intruded apices of the maxillary cheek teeth in another rabbit. The second to fourth maxillary cheek teeth (premolar 2 to molar 1) are affected (white arrows). In addition, the bony part of the lacrimal duct is pathologically distended (red arrow) and the palate is remodelled to accommodate the intruding apices of the maxillary first incisors (green arrow). The occlusal plane is uneven and there is a significant mismatch in its length between maxilla and mandible (red lines). In addition to this, a deformity of one of the mandibular second cheek teeth can be seen, accompanied by a broadening of the caudal interdental space (blue arrow), despite superimposition of the two sides.

The dorsoventral view (▶ Fig. 3b) illustrates a distinct penetration of the zygomatic and lacrimal processes by marked retrograde tooth elongation of four teeth on the left side (white arrows)

whilst just three maxillary cheek teeth are affected on the right (green arrows). The yellow arrows indicate a medial displacement of the apices of the first and second mandibular cheek teeth (right side). Care is required in order to distinguish radiographically between intermandibular retrograde tooth displacement (yellow arrows) and intraoral lingual spur formation (blue arrow) so a thorough intraoral examination is essential at the same time as radiography. As with the previous case, an intraoral mandibular and two oblique radiographs are indicated to further distinguish the pathology.

Guinea Pig

Normal radiographic anatomy of the skull

Anatomical reference lines are also useful in guinea pigs. One connects the rostral end of the nasal bone with the dorsal notch of the tympanic bulla, about three quarters of the height of the bulla (► Fig. 4a). In young guinea pigs the nasal bone forms a nearly straight line with the dorsal skull (orange line), whereas in older

guinea pigs the two meet at a slight angle creating a dorsal concavity where they meet (orange line in ► Figures 5a and 6a).

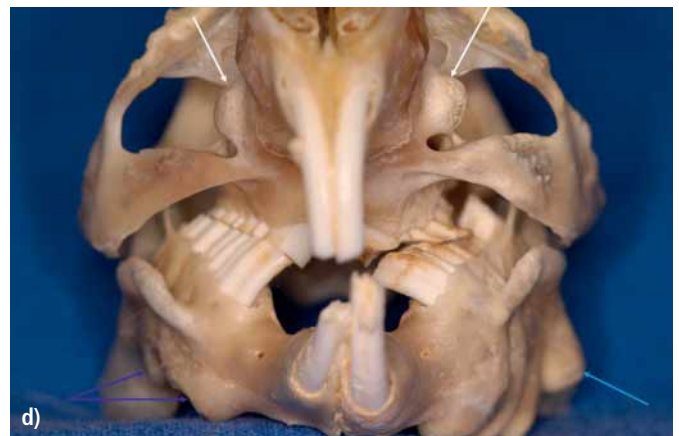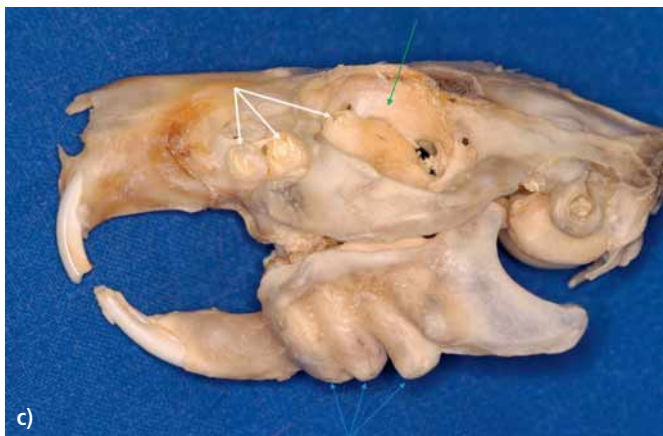
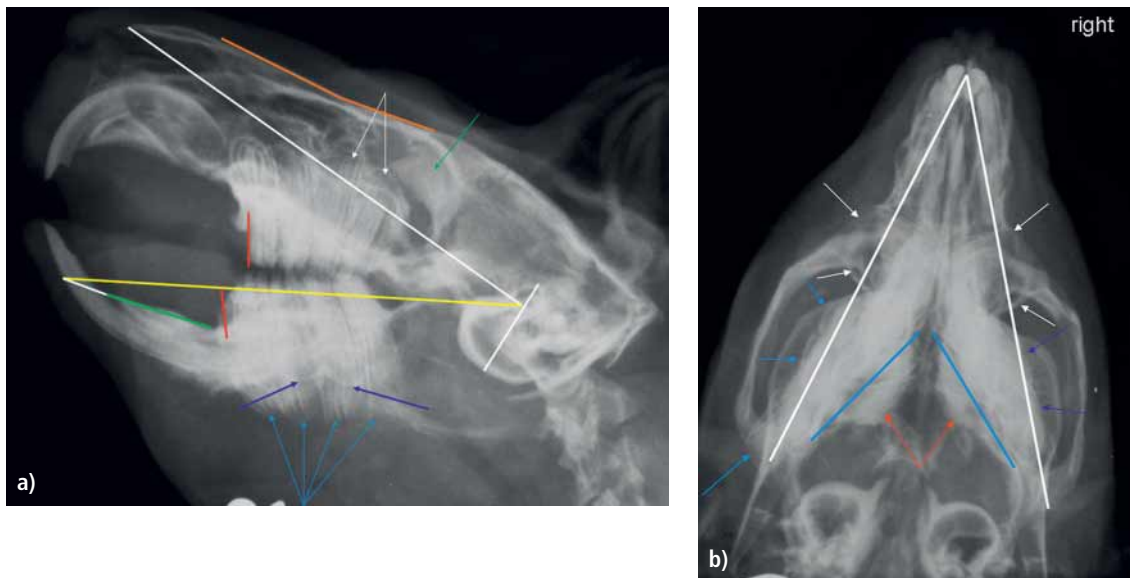
As the occlusal surfaces of guinea pig cheek teeth are strongly angled the occlusal plane does not present as a clear line on the laterolateral skull view (certain vagueness because of superimposition of the medial occlusal part of the upper and the lateral occlusal part of the lower cheek teeth), but it is mostly sufficiently visible to allow comparison with the next reference line. This is drawn from the point on the rostral surface of the mandibular incisor where it is crossed by a line projected cranially from the mandibular bone plate (green line), to the notch of the tympanic bulla (yellow line in ► Fig. 4a). This second reference line runs straight along the occlusal line of the mandibular cheek teeth. If the teeth are truly healthy it should also run through the wear surfaces of the maxillary and mandibular incisors when the mouth is closed, but this is rarely seen in practice as most guinea pigs have at least a minor degree of clinical crown elongation as seen in this case.

As in rabbits, the ventral mandibular cortex (blue line) should not be penetrated by any of the cheek tooth apices which should be

Fig. 5

Guinea pig, 4 years, advanced stage of dental disease. See main text for explanation.

- a) Laterolateral view;
b) dorsoventral view. An incidental finding on this dorsoventral view is thickening of the bone of the left tympanic bulla.
c) Skull lateral view of the left side;
d) rostrocaudal view.



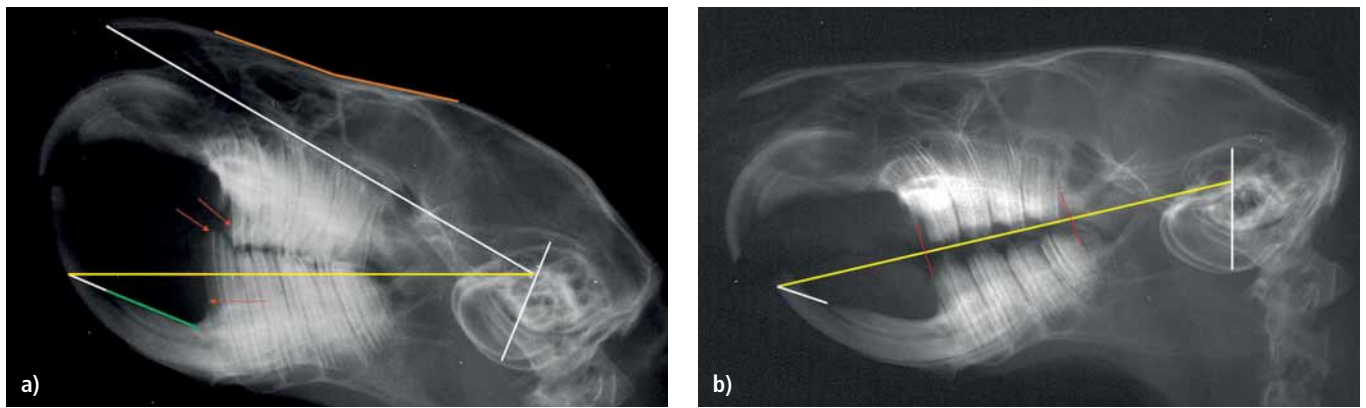


Fig. 6 Guinea pig, 7 months, early stage of dental disease. See main text for explanation. a) Laterolateral view before; b) immediately after trimming the teeth.

distinctly radiolucent. If thinning, distortion or penetration is evident (dark blue arrows), retrograde tooth elongation is present. The guinea pig's oral profile differs from that of rabbits, the palatal and mandibular cortices converge noticeably rostrally when the

mouth is closed (green lines). The greater the degree of intraoral tooth elongation the less obvious this becomes in guinea pigs. The maxillary and mandibular tooth arcs are each formed by four cheek teeth, the maxillary and mandibular arcs being of matching lengths (red lines). A discrepancy between arc lengths is an indicator of significant dental problems in this species.

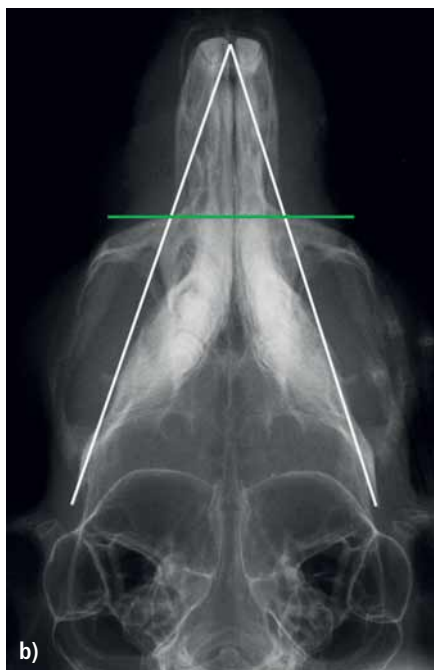
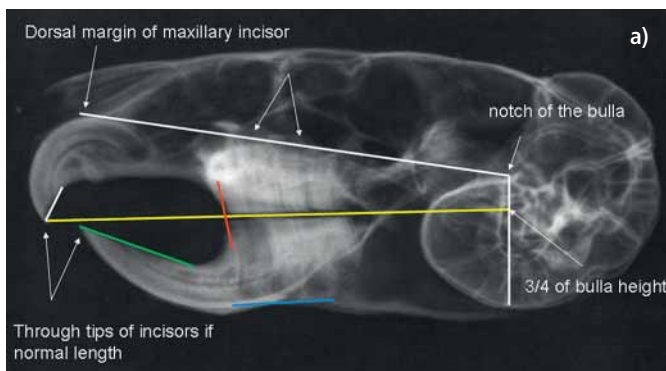


Fig. 7 Reference lines in a healthy chinchilla. See main text for explanation. a) Laterolateral view; b) dorsoventral view.

On the dorsoventral skull view the most informative reference line runs from the mesial border of the maxillary incisor to the most caudolateral part of the ipsilateral mandible, which lies at the level of the temporal zygomatic process (red arrows in ► Fig. 4b). In guinea pigs without any significant tooth elongation only the radiolucent apical bulla of the maxillary first cheek tooth (the premolar) extends beyond this line (white arrows). More caudally the prominent nearly crescent shaped bone structure crossing this line (blue arrows in ► Figures 4b, c and d) is the masseteric ridge of the mandible, where the deep part of the masseter muscle originates. The blue lines in ► Figure 4b indicates the medial cortical borders of the mandibles.

Dental disease

A mature guinea pig (see the angulation in the orange line) with advanced dental changes is shown in ► Figures 5a to 5d. The dorsal reference line clearly demonstrates a retrograde displacement of the reserve crown and apices of the third and fourth maxillary cheek teeth (white arrows in ► Fig. 5a). Dorsocaudal to that area, the radiograph of the skull shows radiodense bone formation that is clearly seen on the dissected skull from this animal (green arrow in ► Figures 5a and 5c).

The rostral point of origin for the second reference line is less precise in this animal due to changes in the mandibular bone plate and rostral tipping of the incisors; however, the line clearly shows an intraoral elongation of the mandibular molars (yellow line). Additionally the apices and reserve crowns of all the cheek teeth on one side have penetrated the ventral mandibular cortex demonstrating marked apical elongation (light blue arrows in ► Figures 5a, c and d). Superimposed over this, cortical thinning and remodelling is clearly seen around the apices of the teeth in the

other mandible (dark blue arrows in ► Figures 5a and d). Mismatch of the cheek tooth arcade lengths is clearly visible (red lines in ► Figure 5a). This is a very reliable sign of significant dental disease, particularly in this species. The mouth can clearly be seen to be in the fully open position in this animal as the rostral mandible and palate are almost parallel.

On the dorsoventral view (► Fig. 5b) the reference lines reinforce the findings from the lateral view: a distinct and generalized retrograde displacement of the reserve crowns and apices of both the mandibular and maxillary cheek teeth is evident (left side > right side). The elongated mandibular molar apices extend beyond the reference line laterally (light and dark blue arrows). The apices and elongated reserve crowns of the maxillary premolar and first molar also cross the reference line in the area of the infraorbital canal (white arrows in ► Figure 5b), with penetration of the bone cortex on the left side as confirmed from the dissected skull of this guinea pig (white arrows in ► Figures 5c and 5d). The light blue arrow in ► Figure 5d points at the mandibular left fourth cheek tooth which has extreme retrograde elongation and deviation. The

second reference line along the medial cortex of the mandible, represented by the blue lines in ► Figure 5b, is crossed medially by some tooth substance (red arrows). This correlates with a combination of probable rostral displacement of the mandible, as occurs accompanying intraoral tooth (clinical crown) elongation in many guinea pigs, and the overlong reserve crowns of the caudal maxillary molars of both sides.

The anatomical reference lines can be very helpful in interpreting post-treatment radiographs. As mentioned above, it is typical for the mandible to be forced rostrally in guinea pigs with intraoral tooth elongation (► Fig. 6a). The yellow reference line in ► Figure 6a shows that the animal's lower cheek teeth are far too long. Extensive shortening and recreation of normal occlusal angulation is necessary for all the mandibular teeth including the incisors, the maxillary teeth then requiring occlusal adjustment to match the mandibular teeth. The goal of treatment is to reach as near to normal occlusion as possible.

In this case the teeth were elongated without other significant changes so the teeth could be returned to near normal as shown by

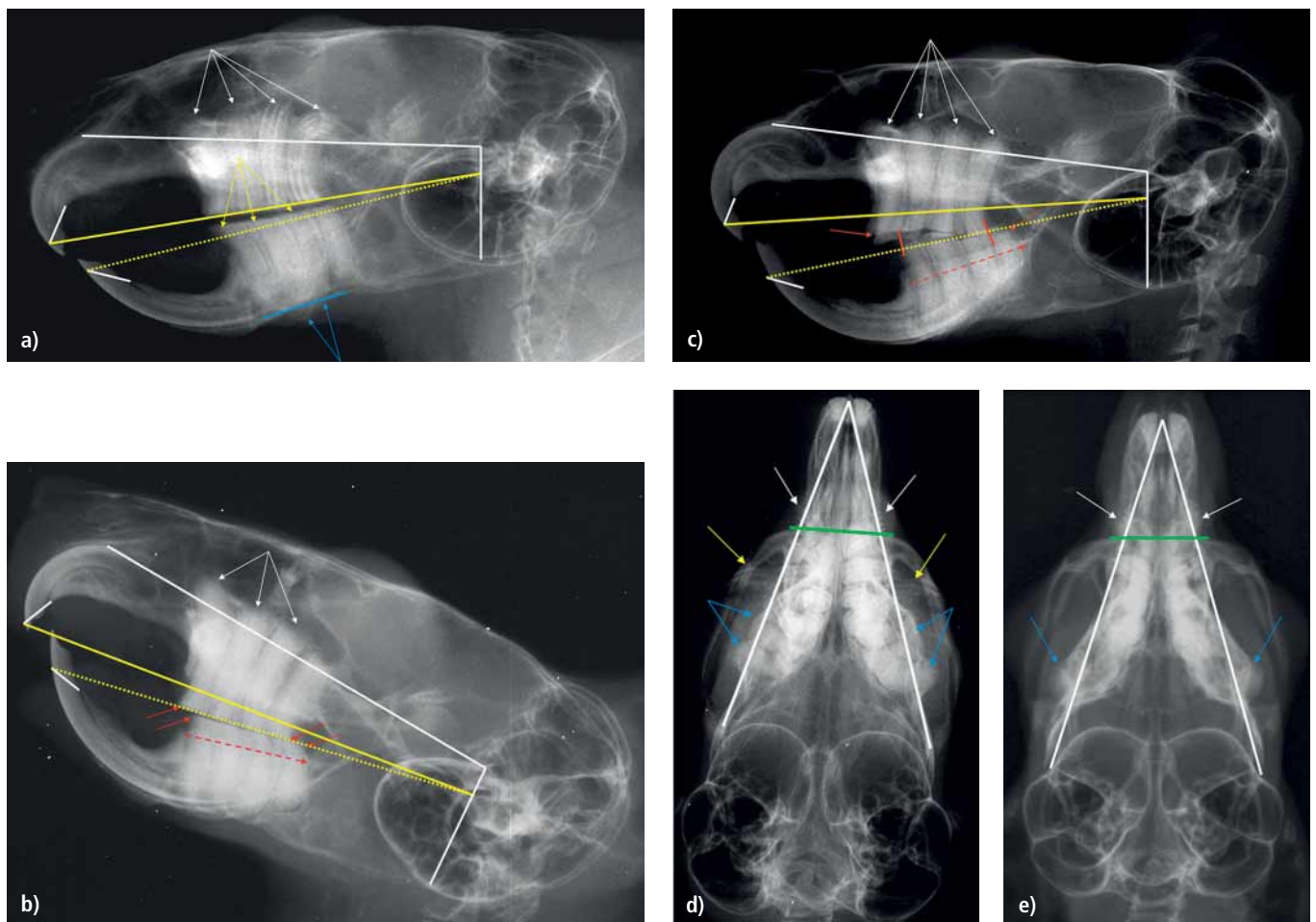


Fig. 8 Chinchillas with different stages of dental disease. See main text for explanation. a) Chinchilla 11 years, early stage of dental disease (laterolateral view); b) Chinchilla 5 years, more advanced dental disease (laterolateral view); c) Chinchilla 2 years, advanced dental disease (laterolateral view); d) Chinchilla 3 years, advanced dental disease (dorsoventral view); e) Chinchilla 5 years, advanced dental disease (dorsoventral view).

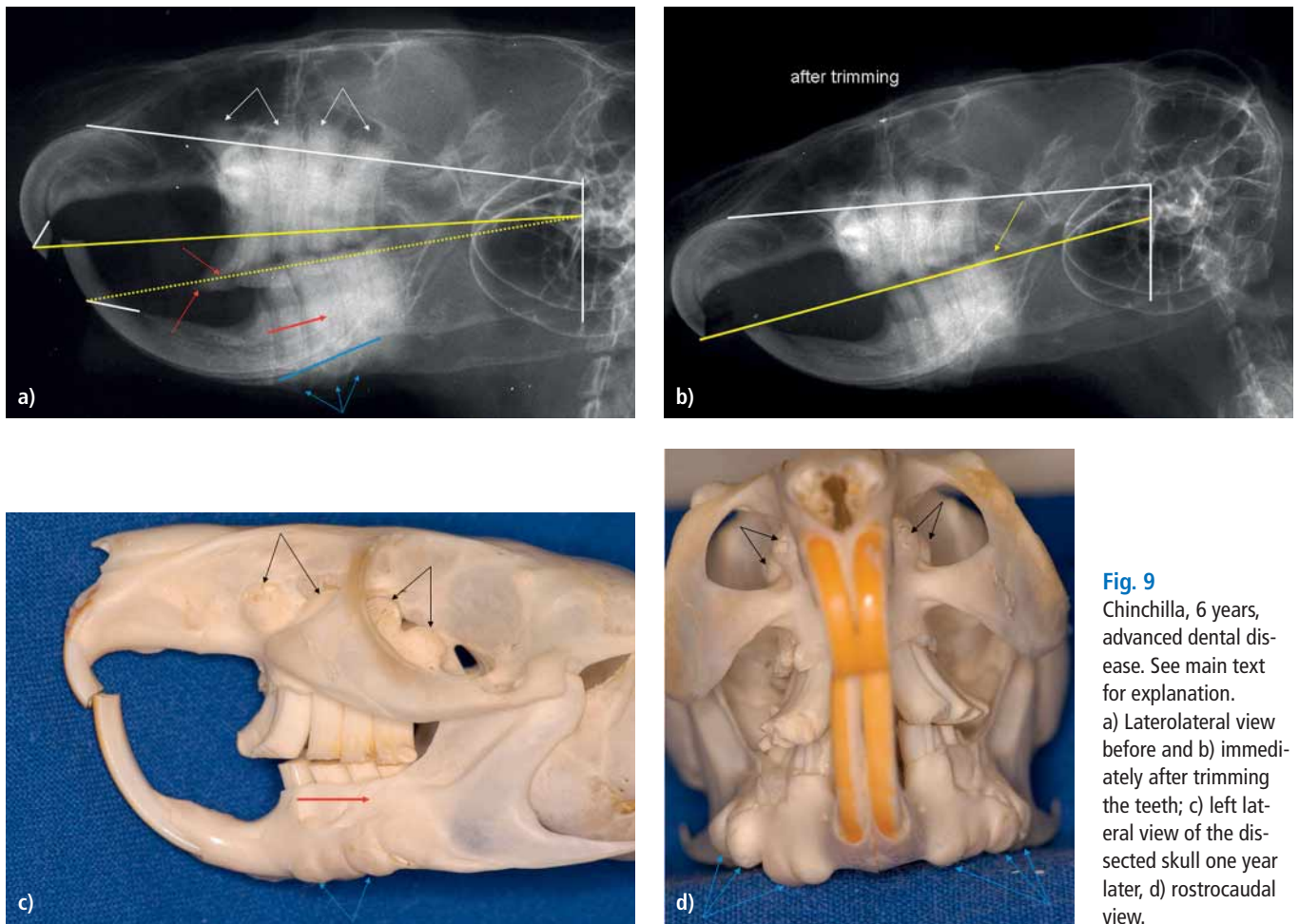


Fig. 9 Chinchilla, 6 years, advanced dental disease. See main text for explanation. a) Laterolateral view before and b) immediately after trimming the teeth; c) left lateral view of the dissected skull one year later, d) rostrocaudal view.

the reference line in ► Figure 6b. Following tooth trimming, the occlusal plane is at near normal height and the maxillary and mandibular tooth arcades are opposite each other and of approximately the same lengths. Critically judged the lower incisors are still a bit too long (white line) and miss typical chisel-shaped tips. Despite a good dental outcome such animals will have some problems chewing in the post-treatment period as the jaw muscles take time to readapt to a shorter working length during which time supportive feeding may be required.

Chinchilla

Normal radiographic anatomy of the skull

The most important reference line in chinchillas connects the dorsal margin of the maxillary incisor with the middle of the tympanic bulla, which is very large in chinchillas (► Fig. 7a). In healthy animals the radiolucent soft tissue at the apices of the maxillary cheek teeth should be on this line, with no calcified tooth structures extending dorsal to it. As most pet chinchillas have retrograde displacement of the cheek tooth apices, it is uncommon to find animals without any abnormalities here.

The second reference line begins at the tip of the upper incisors and extends caudally to pass through the tympanic bulla at approximately three quarters of its height. It runs almost parallel to the palatal bone and passes through the occlusal surfaces or tips of both the incisors when they are of normal length and occlusion (yellow line in ► Fig. 7a). This position will need to be estimated in a manner similar to finding the point of origin on the rostral surface of the mandibular incisor in guinea pigs if the teeth are significantly elongated (green line). The reference line (yellow) coincides with the normal occlusal plane. Due to the physiology of normal chewing the occlusal plane should be horizontal and quite even in this species, resulting in a distinct straight line on laterolateral radiographs of clinically healthy chinchillas.

The third reference line runs near parallel to the occlusal line extending caudally from the most ventral part of the mandibular incisor and corresponds with the ventral mandibular cortex below the apices of the first three cheek teeth (blue line). The ventral border of the mandible should be smooth and even without any thinning or distortions associated with intruded apices.

Reference lines on the dorsoventral view are not as accurate in identifying changes as those for guinea pigs, but are still useful. Lines can be drawn between the medial tip of each maxillary in-

cisor and the caudal extremity of the ipsilateral mandibular ramus (white lines in ► Figure 7b) to mark the lateral limit of cheek teeth in clinically healthy animals. A transverse line drawn through the points where the first lines cross the rostral edge of the maxillary zygomatic processes (green line ► Figure 7b) indicates the most rostral extent of clinically healthy cheek tooth apices.

Dental disease

Although the radiograph in ► Figure 8a does not show major pathological changes, the reference lines clearly indicate that there is significant change present in this chinchilla. The upper line demonstrates an advanced stage of retrograde tooth elongation of all the maxillary cheek teeth (white arrows). The mandibular molar clinical crowns are elongated (broken yellow line and yellow arrows in ► Figure 8a) and need to be shortened. In order to be able to determine the correct rostral end of both yellow lines the length of the upper and lower incisors has to be corrected first (white lines – compare with ► Figure 7a). Note that the increased divergent curvatures rostrally and caudally have elongated the occlusal surfaces. The ventral cortex of the mandible is penetrated by the apices of the second and third cheek teeth (blue arrows). As such apical changes cannot be reversed, ongoing dental problems are expected even if the occlusal surfaces are returned to normal alignment.

Contrary to the situation in guinea pigs with dental disease, where the lower jaw moves rostrally, the mandible typically shifts caudally in chinchillas. This is scarcely visible in ► Figure 8a. Chinchillas with this incongruity have significant dental problems, the degree of mandibular displacement closely correlating with the extent of clinical crown elongation. It represents the combined effects of tooth curvatures and the resultant “open mouth” jaw alignment due to clinical crown elongation. The dental arcades are often displaced by as much as half (red arrows in ► Figure 8b) or even the whole width of a cheek tooth (red arrows in ► Figure 8c).

Dorsoventral views often permit easy detection of changes in dental morphology which can be clearly seen as irregularities of tooth structure and alignment. The blue arrows in ► Figures 8d and 8e point at the intruded apices of the caudal mandibular molars. The white arrows mark the apices of the first two maxillary cheek teeth (premolars) which extend beyond the rostral reference line. Typically, they elongate in an arc and penetrate the maxillary bone in this area, obstructing or obliterating the nasolacrimal ducts. It is important to distinguish clinical crown from apices on this view: the yellow arrows in ► Figure 8d indicate the intraorally and buccally elongated first cheek tooth on both sides in this animal. The clinical crowns appear more lucent compared with the intra-alveolar parts of the cheek teeth which appear relatively radiodense, being surrounded by alveolar bone and soft tissues.

As in guinea pigs, the reference lines permit checking for correct shortening of the cheek teeth. ► Figure 9a shows the laterolateral view of a chinchilla with excessive intra- and extra-oral tooth elongation. The two yellow lines approximate the normal occlusal lines

and clearly indicate how much tooth substance has to be removed (area in between the lines). This is up to one third of the maxillary tooth substance. The corresponding reference line on the post treatment image (► Fig. 9b) shows that the shortening was not entirely successful. The last mandibular molar is still somewhat too long (yellow arrow), but in general the occlusion is much better. It is often difficult to remove sufficient length of tooth as the gingiva has usually grown to cover part of the elongated clinical crowns, so repeated occlusal adjustment should be scheduled before there is further significant elongation to make further adjustments. In cases with gross clinical crown elongation it is preferable to stage treatment, only removing about two third of the measured excess tooth length initially, scheduling completion of treatment 2–3 weeks later. This permits better muscle re-adaptation to the shorter working length and gives time for the gingiva to recede exposing enough crown for more effective occlusal correction.

As the animal had to be euthanized a year later, the dissected skull of this chinchilla was examined (► Figs. 9c and 9d). This demonstrates the generalized intra- and extra-oral elongation of all teeth along with the associated bony changes that were evident on the previous radiographs: retrograde displacement of all the maxillary cheek tooth apices, the accompanying maxillary bone penetration (black arrows), apparent caudal dislocation of the mandible (red arrow) and the ventral distension of the mandibular cortex (blue arrows).

Conclusion

Anatomical reference lines adapted to the particular anatomy of the species enable the veterinarian to more accurately assess and evaluate aspects of dental disease in rabbits, guinea pigs and chinchillas. Reference lines provide an objective measure of tooth elongation which can be demonstrated to owners, permit assessment of prognosis, appropriate treatment planning and assessment of success of treatment for clinical crown elongation. They make it easier for veterinarians to help their elodont patients.

References

1. Boehmer E. Roentgendiagnostik bei Zahn- sowie Kiefererkrankungen der Hasenartigen und Nager. Teil 1: Tierartspezifische Zahn- und Kieferanatomie sowie Pathologie, Indikationen für die Roentgendiagnostik. (X-ray diagnosis of tooth and jaw impairment in lagomorphs and rodents. Part 1: Overall anatomy and pathology of the head area, indications for x-ray diagnosis). *Tieraerztl Praxis* 2001; 29 (K): 316–327.
2. Boehmer E. Roentgendiagnostik bei Zahn- sowie Kiefererkrankungen der Hasenartigen und Nager. Teil 2: Interpretation von Roentgenaufnahmen und tierartspezifische Fallbeispiele. (X-ray of tooth and jaw impairment in lagomorphs and rodents. Part 2: Interpretation of radiographs and case reports). *Tieraerztl Praxis* 2001; 29 (K): 369–383.
3. Brenner ZG, Hawkins MG, Tell LA, et al. Clinical anatomy, radiography and computed tomography on the chinchilla skull. *Comp Cont Educ Pract Vet* 2005; 27: 933–942.

4. Capello V. Extraction of cheek teeth and surgical treatment of periodontal abscessation in pet rabbits with acquired dental disease. *Exotic DVM* 2004; 6 (4): 31–38.
5. Capello V. Diagnosis and treatment of dental disease in pet rabbits and rodents. *J Exot Mammal Med Surg* 2004; 2 (2): 12–19.
6. Capello V. Rabbit and Rodent Dentistry. Zoological Education Network 2005.
7. Crossley DA. Clinical aspects of lagomorph dental anatomy: The rabbit (*Oryctolagus cuniculus*). *J Vet Dent* 1995; 12 (4):137–140.
8. Crossley DA. Clinical aspects of rodent dental anatomy. *J Vet Dent* 1995; 12 (4): 131–135.
9. Crossley DA. Dental disease in rabbits. *Vet Rec* 1995; 137: 384.
10. Crossley DA. Diagnosis of malocclusion in rabbits and rodents. Script, BPT Seminar on Dentistry, Hamburg 1996.
11. Crossley DA, Dubielzig RR, Benson KG. Caries and odontoclastic resorptive lesions in a chinchilla (*Chinchilla lanigera*). *Vet Rec* 1997; 141 (27): 337–339.
12. Crossley DA, Jackson A, Yates J, Boydell IP. Use of computed tomography to investigate cheek tooth abnormalities in chinchillas (*Chinchilla labigera*). *J Small Anim Pract* 1998; 39 (8): 385–389.
13. Crossley DA. Rabbit and rodent radiology. In: *An Atlas of Veterinary Dental Radiology*. DeForge DH, Colmery BH III, eds. Ames: Iowa State University Press 2000; 247–259.
14. Crossley DA, del Mar Miguez M. Skull size and cheek-tooth length in wild-caught and captive-bred chinchillas. *Archiv Oral Biol* 2001; 46: 919–928.
15. Crossley DA. Dental disease in chinchillas in the UK. *J Small Anim Pract* 2001; 42 (1): 12–19.
16. Crossley DA. Dental disease in chinchillas. Thesis, University of Manchester 2003.
17. Crossley DA. Oral biology and disorders of lagomorphs. *Vet Clin North Am: Exot Anim Pract* 2003; 6 (3): 629–659.
18. Crossley DA. Dental disease in chinchillas in the UK. *Europ J Comp Anim Pract* 2003; 13: 57–65.
19. Gloeckner B. Untersuchungen zur Ätiologie und Behandlung von Zahn- und Kiefererkrankungen beim Heimtierkaninchen. (Aetiology and therapy of diseases of teeth and jaw of pet rabbits). Diss Berlin 2002.
20. Gorrel C, Verhaert L. Zahnerkrankungen bei Hasenartigen (Lagomorpha) und Nagetieren (Rodentia). In: *Zahnmedizin bei Klein und Heimtieren*. Gorrel C, ed. Urban & Fischer 2006; 189–212.
21. Greenberg T. Premolar extraction in the domestic rabbit. *Exotic DVM* 2000; 2 (4): 11.
22. Harcourt-Brown FM. A review of clinical conditions in pet rabbits associated with their teeth. *Vet Rec* 1995; 137: 341–346.
23. Harcourt-Brown FM. Calcium deficiency, diet and dental disease in pet rabbits. *Vet Rec* 1996; 139: 367–371.
24. Harcourt-Brown FM. Diagnosis, treatment and prognosis of dental disease in pet rabbits. In *pract* 1997; 19: 407–421.
25. Harcourt-Brown FM. Treatment of facial abscesses in rabbits. *Exotic DVM* 1999; 1 (3): 83–88.
26. Harcourt-Brown FM, Baker SJ. Parathyroid hormone, haematological and biochemical parameter in relation to dental disease and husbandry in rabbits. *J Small Anim Pract* 2001; 42 (3): 130–136.
27. Harcourt-Brown FM. Dental disease. In: *Textbook of Rabbit Medicine*. Harcourt-Brown FM, ed. Oxford: Butterworth Heinemann 2002; 165–205.
28. Harcourt-Brown FM. Anorexia in rabbits. 1) Causes and effects. In *Pract* 2002; 24: 358–367.
29. Harcourt-Brown FM. Anorexia in rabbits. 2) Diagnosis and treatment. In *Pract* 2002; 24: 450–467.
30. Harcourt-Brown FM. Metabolic bone disease as a possible cause of acquired dental disease in pet rabbits. Thesis 2005.
31. Harcourt-Brown FM. The progressive syndrome of acquired dental disease in rabbits. *J Exot Pet Med* 2007; 16 (3): 146–157.
32. Hernandez-Divers SJ. Molar disease and abscesses in rabbits. *Exotic DVM* 2001; 3 (3): 65–69.
33. Legendre LF. Malocclusions in guinea pigs, chinchillas and rabbits. *Canadian Vet J* 2002; 43: 385–390.
34. Legendre LF. Oral disorders of exotic rodents. *Vet Clin North Am Exot Anim Pract* 2003; 6: 601–628.
35. Lobprise HB, Wiggs RB. Dental and oral disease in lagomorphs. *J Vet Dent* 1991; 8: 11–17.
36. Loic FJ Legendre. Oral disorders of exotic rodents. *Vet Clin North Am Exot Anim Pract* 2003; 6 (3): 601–628.
37. Schaeffer DO, Donnelly TM. Disease problems in guinea pigs and chinchillas. In: *Ferrets, Rabbits and Rodents – Clinical Medicine and Surgery*. Hillyer EV, Quesenberry KE, eds. Philadelphia: Saunders 1997; 260–281.
38. Silverman S, Tell LA. Radiology of Rodents, Rabbits and Ferrets – An Atlas of Normal Anatomy and Positioning. Philadelphia: Elsevier Saunders 2005.
39. Taylor M. A wound packing technique for rabbit dental abscesses. *Exotic DVM* 2003; 5 (3): 28–31.
40. Verstraete FJM. Advances in diagnosis and treatment of small exotic mammal dental disease. *Sem Avian Exot Pet Med* 2003; 12 (1): 37–48.
41. Verstraete FJM, Osofsky A. Dentistry in pet rabbits. *Comp Cont Educ Pract Vet* 2005; 27 (9): 671–685.
42. Wiggs RB, Lobprise HB. Dental disease in rodents. *J Vet Dent* 1990; 7 (3): 6–8.
43. Wiggs RB, Lobprise HB. Dental and oral disease in lagomorphs. *J Vet Dent* 1991; 8 (2): 11–17.
44. Wiggs RB, Lobprise HB. Dental anatomy and physiology of pet rodents and lagomorphs. In: *Manual of Small Animal Dentistry*, 2nd ed. Crossley DA, Penman S, eds. Cheltenham: BSAVA 1995; 68–73.
45. Wiggs RB, Lobprise HB. Dental and oral disease in rodents and lagomorphs. In: *Veterinary Dentistry – Principles & Practice*. Wiggs RB, Lobprise HB, eds. Lippincott: Philadelphia 1997; 518–537.